

Blood perfusion of patellar bone measured by dynamic contrast-enhanced MRI in patients with patellofemoral pain

A case-control study

van der Heijden, Rianne A.; Poot, Dirk H.J.; Ekinci, Melek; Kotek, Gyula; van Veldhoven, Peter L.J.; Klein, Stefan; Verhaar, Jan A.N.; Krestin, Gabriel P.; Bierma-Zeinstra, Sita M.A.; van Middelkoop, Marienke

DOI

[10.1002/jmri.26174](https://doi.org/10.1002/jmri.26174)

Publication date

2018

Document Version

Final published version

Published in

Journal of Magnetic Resonance Imaging

Citation (APA)

van der Heijden, R. A., Poot, D. H. J., Ekinci, M., Kotek, G., van Veldhoven, P. L. J., Klein, S., Verhaar, J. A. N., Krestin, G. P., Bierma-Zeinstra, S. M. A., van Middelkoop, M., & Oei, E. H. G. (2018). Blood perfusion of patellar bone measured by dynamic contrast-enhanced MRI in patients with patellofemoral pain: A case-control study. *Journal of Magnetic Resonance Imaging*, *48*(5), 1344-1350. <https://doi.org/10.1002/jmri.26174>

Important note

To cite this publication, please use the final published version (if applicable). Please check the document version above.

Copyright

Other than for strictly personal use, it is not permitted to download, forward or distribute the text or part of it, without the consent of the author(s) and/or copyright holder(s), unless the work is under an open content license such as Creative Commons.

Takedown policy

Please contact us and provide details if you believe this document breaches copyrights. We will remove access to the work immediately and investigate your claim.

Blood Perfusion of Patellar Bone Measured by Dynamic Contrast-Enhanced MRI in Patients With Patellofemoral Pain: A Case–Control Study

Rianne A. van der Heijden, MD, PhD,^{1,2} Dirk H.J. Poot, PhD,^{3,4} Melek Ekinci, MSc,¹
Gyula Kotek, PhD,² Peter L.J. van Veldhoven, MD,⁵ Stefan Klein, PhD,³
Jan A.N. Verhaar, MD, PhD,⁶ Gabriel P. Krestin, MD, PhD,²
Sita M.A. Bierma-Zeinstra, PhD,^{1,6} Marienke van Middelkoop, PhD,¹ and
Edwin H.G. Oei, MD, PhD^{2*}

Background: Altered perfusion might play an important role in the pathophysiology of patellofemoral pain (PFP), a common knee complaint with unclear pathophysiology.

Purpose: To investigate differences in dynamic contrast-enhanced (DCE)-MRI perfusion parameters between patients with PFP and healthy control subjects.

Population/Subjects/Phantom/Specimen/Animal Model: Thirty-five adult patients with PFP and 44 healthy adult control subjects.

Field Strength/Sequence: 3T DCE-MRI consisting of a sagittal, anterior-posterior, frequency-encoded, fat-suppressed 3D spoiled gradient-echo sequence with intravenous contrast administration.

Assessment: Patellar bone volumes of interest (VOIs) were delineated by a blinded observer. Quantitative perfusion parameters (k_{ep} and k_{trans}) were calculated from motion-compensated DCE-MRI data by fitting Tofts' model. Weighted mean and unweighted median values of k_{ep} and k_{trans} were computed within the patellar bone VOIs.

Statistical Tests: Differences in patellar bone perfusion parameters were compared between groups by linear regression analyses, adjusted for confounders.

Results: Mean differences of weighted mean and unweighted median were 0.0039 (95% confidence interval [CI] –0.0013; 0.0091) and 0.0052 (95% CI –0.0078; 0.018) for k_{trans} , and 0.046 (95% CI –0.021; 0.11) and 0.069 (95% CI –0.017; 0.15) for k_{ep} , respectively.

All perfusion parameters were not significantly different between groups (P -values: 0.32; 0.47 for k_{trans} , and 0.24; 0.15) for k_{ep} . However, a significant difference in variance between populations was observed for k_{trans} (P -value 0.007).

Data Conclusion: Higher patellar bone perfusion parameters were found in patients with PFP when compared to healthy control subjects, but these differences were not statistically significant. This result, and the observed significant difference in k_{trans} variance, warrant further research.

Level of Evidence: 1

Technical Efficacy: Stage 3

J. MAGN. RESON. IMAGING 2018;48:1344–1350.

View this article online at wileyonlinelibrary.com. DOI: 10.1002/jmri.26174

Received Feb 2, 2018, Accepted for publication Apr 16, 2018.

*Address reprint requests to: E.H.G.O., Department of Radiology & Nuclear Medicine, Erasmus MC, University Medical Center Rotterdam, P.O. Box 2040, 3000 CA Rotterdam, the Netherlands. E-mail: e.oei@erasmusmc.nl

From the ¹Department of General Practice, Erasmus MC, University Medical Center, Rotterdam, The Netherlands; ²Department of Radiology & Nuclear Medicine, Erasmus MC, University Medical Center, Rotterdam, The Netherlands; ³Biomedical Imaging Group Rotterdam, Departments of Medical Informatics & Radiology, Erasmus MC, Rotterdam, The Netherlands; ⁴Quantitative Imaging, Department of Imaging Physics, TU Delft, Delft, The Netherlands; ⁵Department of Sports Medicine, Medical Center Haaglanden, Leidschendam, The Netherlands; and ⁶Department of Orthopedics Erasmus MC, University Medical Center, Rotterdam, The Netherlands

This is an open access article under the terms of the Creative Commons Attribution-NonCommercial License, which permits use, distribution and reproduction in any medium, provided the original work is properly cited and is not used for commercial purposes.

Patellofemoral pain (PFP) is a common knee complaint, especially in young physically active individuals,¹ and is characterized by retropatellar or peripatellar pain during kneeling, stair climbing, running, cycling, squatting, and prolonged sitting with the knees flexed. A substantial percentage of patients with PFP experience persistent symptoms.^{2,3} While the pathophysiology of PFP is still unknown and, consequently, targeted therapy is lacking,^{4–7} an increasing body of research suggests that altered perfusion might play a role. Both impaired arterial inflow and impaired venous outflow of blood have been implicated in the development of PFP.^{8–14}

Contemporary imaging enables quantitative measurement of perfusion. For instance, dynamic contrast-enhanced (DCE) magnetic resonance imaging (MRI) is routinely applied in clinical practice for tumor and cerebral stroke imaging.^{15,16} Although DCE-MRI can also be applied to bone, there have only been a limited number of published DCE-MRI studies for bone and even fewer that used a quantitative approach on MRI data of the lower extremity in humans.^{17–22} This might be due to major challenges for the implementation of quantitative DCE-MRI in bone, such as the relatively poor vascularization of bone and the typical low contrast enhancement compared to surrounding tissues.

In order to adequately measure perfusion parameters, MRI data have to be extracted and fitted by a pharmacokinetic model that suits the MRI data. Poot et al.²⁵ recently published a study comparing multiple pharmacokinetic models, such as Brix et al.,²³ Tofts and Kermode,²⁴ and extended Tofts' model, applied on DCE-MRI of the patellar bone, in which the Tofts' model was identified as the best model.²⁵ Until now, this quantitative DCE-MRI approach has not been applied in a clinical setting in a large cohort. Application of this method in a large cohort of patients with PFP and control subjects may lead to a better understanding of the pathophysiology of PFP.

Therefore, the purpose of this study was to investigate differences in patellar bone blood perfusion, measured with quantitative DCE-MRI, between patients with PFP and control subjects.

Materials and Methods

Study Design and Participants

For the current study purpose, patients aged 18–40 years with PFP and healthy control subjects were included between January 2013 and September 2014. Patients with PFP for 2 months to 2 years diagnosed by their general practitioner, physiotherapist, or sports physician, based on the presence of at least three of the following symptoms: crepitus or retropatellar or peripatellar pain during stair climbing, squatting, running, cycling, or sitting for a prolonged period with flexed knees were included.²⁶ Exclusion criteria were: previous PFP episodes more than 2 years ago, onset after trauma, defined pathological condition of the affected knee at present, for

instance patellar tendinopathy or Osgood-Schlatter disease, or previous surgery or injury of the affected knee. Healthy controls were recruited from patients' sports team members, friends, or colleagues. We sought to match patient and controls on age, gender, body mass index (BMI), and activity level. Exclusion criteria for controls were: present or past PFP, surgery or traumatic injury of both knees, or first-degree relatedness with patients. Other exclusion criteria were: contraindications for contrast-enhanced MRI and insufficient knowledge of the Dutch language. Written informed consent was obtained and this study was approved by our Institutional Review Board.

Measurements

Participants completed a questionnaire on demographics, sports participation (yes/no), and knee complaints (duration, bilateral pain, Anterior Knee Pain Scale [AKP]) 0–100²⁷ and underwent 3T MRI (Discovery MR750, GE Healthcare, Milwaukee, WI) using a dedicated 8-channel knee coil (InVivo, Gainesville, FL) at our institution. The (most) symptomatic knee of PFP patients was selected, or randomly chosen if both knees were equally painful or if both were asymptomatic (controls). The MRI protocol consisted of routine clinical proton density and T₂-weighted fat-saturated sequences in three orthogonal planes, and a 3D spoiled gradient-echo (SPGR) sequence with in-plane resolution of 0.29 mm. DCE-MRI was acquired, consisting of a sagittal, anterior-posterior, frequency-encoded, fat-suppressed 3D SPGR sequence, 35 phases of 10 seconds with intravenous contrast administration (0.2 mmol/kg Magnevist; Bayer, Berlin, Germany) at 2 ml/s starting after the first phase. Other parameters were: field of view 38 × 38 cm, acquisition matrix of 256 × 128, zero filled to 256 × 256, in-plane resolution 1.5 mm, slice thickness 5 mm.

Image Analysis

DCE-MRI measures the amount of contrast enhancement, based on signal intensity, over time in a specific volume of interest (VOI) as a measure of blood perfusion.²² Our VOI consisted of the entire patellar bone marrow (Fig. 1), which was manually delineated on the 3D SPGR nonfat-saturated MR images with MatLab (R2011a, MathWorks, Natick, MA) by an experienced blinded observer.^{28,29} Elastix was used to correct for rigid motion of the patella during MRI acquisition as well as to rigidly map the DCE acquisition to the SPGR.³⁰ Perfusion was visualized semiquantitatively by means of a time–intensity curve. Since a groupwise AIF was used, the delay between the arterial input function and the start of contrast enhancement incorporated both dispersion/delay of the contrast between injection and arrival in the patella as well as injection time differences. Thus, time–intensity curves were synchronized to facilitate comparison. Per subject, the mean of the synchronized time–intensity curve was computed over the VOI. Subsequently, these were normalized to baseline intensity and the group mean and 95% confidence interval (CI) were computed. Furthermore, quantitative analyses were performed by fitting a pharmacokinetic mode.²⁴ Tofts' model combined with a groupwise arterial input function (AIF) was applied, since this combination best fits the patellar bone according to the recent study by Poot et al.³¹ This model uses the AIF from the popliteal artery and assumes one tissue compartment and one vascular compartment (Fig. 2).²⁴ K_{trans}

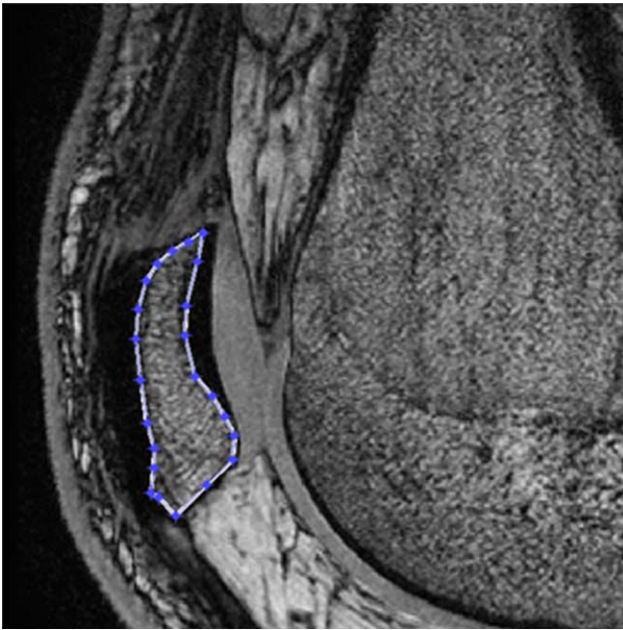


FIGURE 1: Single slice of the VOI of the patellar bone marrow.

reflects the volume transfer constant into the tissue compartment, while k_{ep} describes the rate constant back to the vascular component. Voxelwise fitting was performed using a maximum-likelihood (ML) estimator,³² which takes into account the differences in time required for the contrast agent to reach each voxel.²⁴ Goodness of fit was assessed by comparing the residual over the entire dataset to the acquisition noise level. To aggregate the voxelwise perfusion parameters over the VOI, both weighted means and unweighted medians were computed. For the weighted mean, the reciprocal Cramér-Rao-Lower-Bound (indicating fit uncertainty) was used as weight, in order to assign a lower weight to voxels with high fit uncertainty and obtain a minimum-variance estimate of the VOI mean.³¹ Since this uncertainty-based weight is dependent on the degree of blood perfusion (better perfused areas have a better fit) and could therefore be biased, we additionally calculated the medians of both perfusion parameters, henceforth referred to as “unweighted” median for the avoidance of doubt. Thus, weighted mean and unweighted median of k_{trans} and k_{ep} over the VOI in each participant were computed and these VOI measures of k_{trans} and k_{ep} were used in the group comparisons.

Statistical Analysis

Independent sample *t*-tests and chi-square tests, or Mann–Whitney *U*-test if distribution was not normal, were applied to investigate

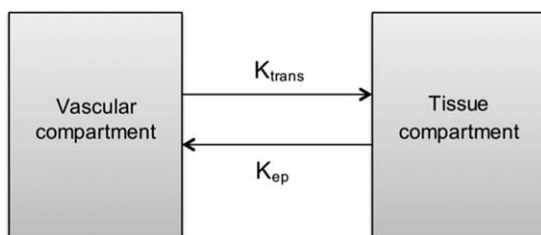


FIGURE 2: Schematic representation of Tofts' pharmacokinetic model.

differences in baseline characteristics between groups. Differences in perfusion parameters (k_{ep} and k_{trans}) were compared between groups by linear regression analyses, adjusted for age, gender, BMI, and sports participation. Logarithmic transformations of weighted mean and median k_{trans} were performed to acquire normal distributions. Due to the presence of negative values, median k_{ep} was not transformed logarithmically, but tested nonparametrically with a Mann–Whitney *U*-test. Differences in variance of perfusion parameters across subjects were tested with Levene's test. Additional adjusted regression analyses were conducted to investigate differences in perfusion parameters between patients with and without sitting pain. Item 8 of the AKP score was used to define sitting pain. Two categories were formed from five possible responses: 1) no sitting pain (“no difficulty” or “pain after exercise”); and 2) sitting pain (“constant pain,” “pain forces to extend the knees temporarily,” or “unable”). Furthermore, correlation between perfusion parameters and AKP score was assessed in patients using Pearson's correlation coefficient in case of normal distribution and Spearman's correlation if not. We calculated mean, standard deviation (SD), and mean differences with 95% CIs. *P*-values < 0.05 were considered statistically significant. All analyses were performed with SPSS v. 20.0 (Chicago, IL).

Results

Participants

Thirty-five adult PFP patients and 44 adult control subjects were included in this analysis, since DCE-MRI data were only acquired in adult participants. Mean age was 26.1 (range 18–40, SD 5.0) years, mean BMI was 24.1 (SD 3.4) kg/m^2 and 49% were female. The BMI was significantly higher in the patient group (Table 1). Patients reported a mean duration of complaints of 11.2 months and 45.7% reported bilateral pain. Mean AKP score of patients was 68. 77.1% of the patients reported the presence of sitting pain.

DCE-MRI

The pharmacokinetic model captured the dynamic signal over the entire dataset and the residual was close to the acquisition noise level.

Figure 3 shows the normalized mean time–intensity curves for patients and controls. The curve of the patient group appeared to have a slightly larger amplitude compared to controls. The rest of the shape of the curve was not noticeably different between groups. 95% CIs of the curves showed an overlap over the entire trajectory.

Quantitative analysis demonstrated a group mean of weighted mean k_{trans} of 0.017 (SD 0.014) min^{-1} for patients and 0.013 (SD 0.008) min^{-1} for control subjects. The group mean of the weighted mean k_{ep} was 0.19 (SD 0.16) min^{-1} for patients and 0.14 (SD 0.14) min^{-1} for control subjects. The group mean of unweighted median k_{trans} was 0.029 (SD 0.028) min^{-1} for patients and 0.023 (SD 0.030) min^{-1} for control subjects. The group mean of the unweighted median k_{ep} was 0.19 (SD 0.23) min^{-1} for patients and 0.11 (SD 0.16) min^{-1} for control subjects

TABLE 1. Characteristics of Study Participants

	Patients (N= 35)	Controls (N= 44)	P-value
Female gender <i>n</i> (%)	18 (51.4)	21 (47.7)	0.74
Age (years) Mean (SD)	26.4 (5.6)	25.9 (4.6)	0.53
BMI (kg/m ²) Mean (SD)	25.1 (3.8)	23.3 (2.8)	0.01
Sports participants			0.39
during inclusion <i>n</i> (%)	24 (68.6)	34 (77.3)	
before onset of pain <i>n</i> (%)	32 (91.4)	n.a.	
Duration of complaints Mean (SD)	11.2 (6.3)	n.a.	n.a.
Bilateral pain <i>n</i> (%)	16 (45.7)	n.a.	n.a.
AKP score Mean (SD)	68.6 (11.0)	n.a.	n.a.
Sitting pain <i>n</i> (%)	27 (77.1)	0 (0)	n.a.

n.a.: not applicable.

(Table 2, Fig. 4). The means of both quantitative perfusion parameters were not statistically significantly different between patients and control subjects and the same applied to the median (Table 2). The spread of unweighted median values across subjects was larger than the spread in weighted mean values (Table 2, Fig. 4). A significant difference in variance across subjects of weighted mean k_{trans} was observed between populations ($P = 0.007$).

Additional analyses with respect to AKP score showed no significant correlation between perfusion parameters and AKP score (Table 3). Furthermore, no significant differences in perfusion parameters between patients with and without pain during sitting were demonstrated (data not shown).

Discussion

This case-control study showed higher values of quantitative DCE-MRI-derived perfusion parameters in patellar bone in

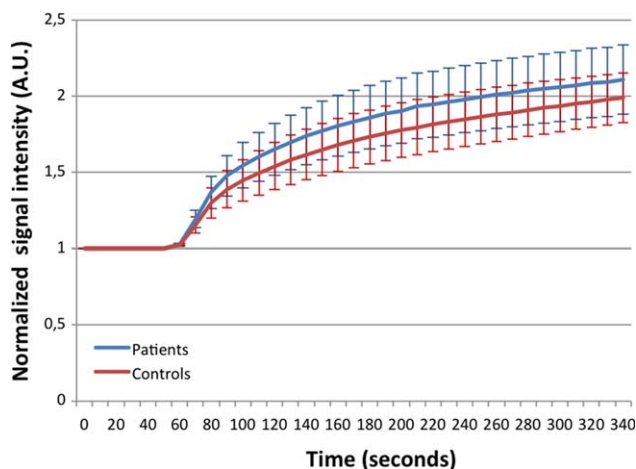


FIGURE 3: Normalized mean synchronized time-intensity curves and corresponding 95% CIs for patients and controls.

PFM patients compared to healthy control subjects, but these differences were not statistically significant. This suggests that patients with PFM do not seem to have a reduced arterial blood inflow or reduced venous outflow, as previously suggested,⁸⁻¹⁴ since this would have been reflected by lower perfusion values.

The larger variance of weighted mean k_{trans} in patients compared to controls, comprising higher k_{trans} values in particular, suggests that a subgroup with higher k_{trans} values might exist within the patient population. Higher k_{trans} values correspond with hyperperfusion; more blood flowing into the patellar bone marrow. This might lead to an increased intraosseous pressure in patients with higher arterial inflow and normal venous outflow, which is supposed to cause pain by stimulation of baroreceptors. Therefore, the cause of hyperperfusion needs to be studied further. Hypervascularization could be a possible explanation for hyperperfusion. It has been hypothesized by Sanchis-Alfonso et al that episodes of ischemia, possibly due to vascular torsion during sitting, could trigger hypervascularization of the patellar retinaculum in maltracking patients with PFM as a result of increased vascular endothelial growth factor release.³³ This might also be applicable for the patellar bone. Another explanation for hyperperfusion could be the presence of bone marrow lesions (BMLs). Lee et al demonstrated increased blood inflow and impaired “washout,” which can be interpreted as stasis or outflow obstruction, in BMLs compared to normal bone in adult patients with osteoarthritis or avascular necrosis with painful bone marrow edema.¹⁹ Additional analysis concerning possible patient subgroups, ie, sitting pain or low AKP score, did not show significant differences. However, with respect to sitting pain, only eight patients of 35 had no sitting pain, and thus there was a lack of power. Future research might focus on the

TABLE 2. Group Mean and Standard Deviation of Weighted Mean Over VOI for k_{ep} and k_{trans} (min^{-1}) and Group Mean and Standard Deviation of Unweighted Median Over VOI k_{ep} and k_{trans} of Patellar Bone in Patients and Controls

	Patients (N= 35)	Controls (N= 44)	Mean difference (95% CI)	Adjusted P-value
K_{trans} (min^{-1})				
Weighted mean	0.017 (0.014)	0.013 (0.008)	0.0039 (-0.0013 ; 0.0091)	0.32
Unweighted median	0.029 (0.028)	0.023 (0.030)	0.0052 (-0.0078 ; 0.018)	0.47
K_{ep} (min^{-1})				
Weighted mean	0.19 (0.16)	0.14 (0.14)	0.046 (-0.021 ; 0.11)	0.24
Unweighted median	0.19 (0.23)	0.11 (0.16)	0.069 (-0.017 ; 0.15)	0.15 ^a

All were adjusted for age, gender, BMI and sports participation. CI: confidence interval.
^aNonparametric testing.

correlation between (combinations of) morphologic parameters and specific perfusion patterns and/or on perfusion of other patellofemoral joint tissues.

The aforementioned study of Poot et al optimized the DCE-MRI method for patellar bone in a small subset, but did not apply this method in a large cohort in a clinical setting.³¹ One previous study has evaluated blood perfusion of bone of the knee joint in humans using a quantitative DCE-MRI approach in a clinical setting.¹⁷ Seah et al applied quantitative DCE-MRI in knee osteoarthritis patients and found

no association between perfusion of tibial BMLs and pain.¹⁷ Their results, however, cannot be directly compared to ours. This is mainly due to the use of a different pharmacokinetic model, Brix instead of Tofts, a different region of interest, tibial BMLs instead of patellar bone, and the fact that they studied bone marrow lesions and not normal bone. Two other studies used Tofts' model in the femur, showing quite different values compared to ours, likely explained by a different blood perfusion between femur and patella.^{20,21}

A major strength and novelty of this study is the application of a tailored quantitative DCE-MRI approach in a large number of relatively young individuals with and without PFP. Furthermore, in contrast to previous studies, an optimized method for patellar DCE-MRI data was used as proposed by Poot et al.³¹

There are also some limitations that need to be addressed. It is important to place these into perspective, however, since

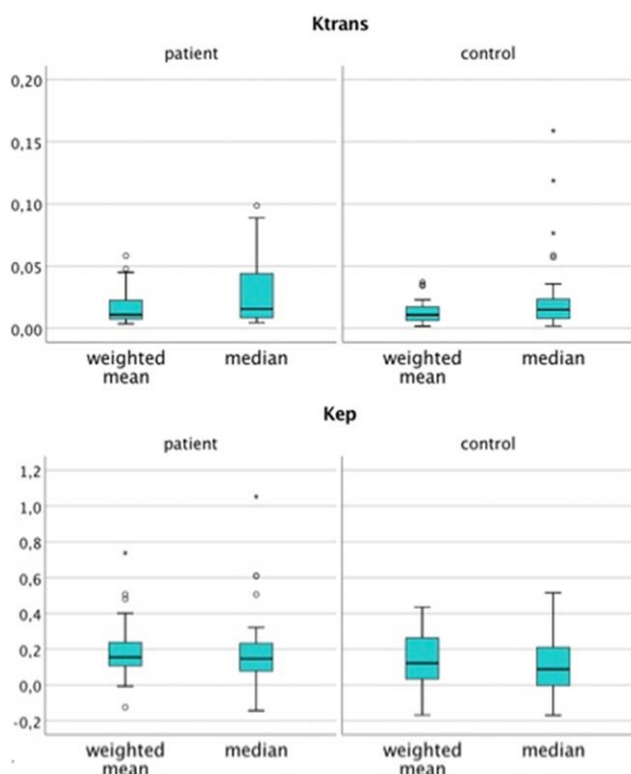


FIGURE 4: Boxplots of weighted mean and unweighted median k_{trans} and k_{ep} (min^{-1}) subdivided in patients and controls.

TABLE 3. Correlation Between the AKP Score and Weighted Mean of k_{ep} and k_{trans} (min^{-1}) and Unweighted Median of k_{ep} and k_{trans} of Patellar Bone in Patients

	Correlation coefficient	P-value
K_{trans} (min^{-1})		
Weighted mean	0.20	0.25 ^a
Unweighted median	0.14	0.42 ^a
K_{ep} (min^{-1})		
Weighted mean	0.02	0.93
Unweighted median	0.02	0.92 ^a

^aNonparametric testing.

DCE-MRI of bone is novel and is still an emerging field of research posing significant challenges. First, although we aimed to match patients and controls on age, gender, BMI, and sports participation, differences were observed in BMI. Therefore, all analyses, besides median k_{ep} , were adjusted for these confounders. Adjustment for confounders was not possible for median k_{ep} , due to nonparametric testing. However, as all confounders in the regression analysis of median k_{ep} were not statistically significant and had low regression coefficients, we believe that the Mann–Whitney U -test was used appropriately. Second, histograms showed a high spatial heterogeneity of patellar blood perfusion, which could potentially lead to a biased weighted mean due to underweighting of less-perfused areas. Therefore, we decided to additionally calculate the unweighted medians of both perfusion parameters. The results showed indeed a small difference between the group mean of the weighted mean and the unweighted median. Weighting was implemented in order to obtain a minimum-variance estimate of the VOI mean,³¹ although, and as expected, the weighted mean had a lower variance compared to the unweighted median. Consequently, since no ground truth is available, analyses took place on both values. It was expected that if large areas of altered perfusion were present, this would have emerged in one of these values. Additionally, based on the high spatial heterogeneity, segmenting the patella into subregions would have been of interest; however, this was not possible due to spatial resolution restrictions. Finally, a large intersubject variability, possibly caused by measurement variability or normal tissue heterogeneity, makes detecting small but significant differences more difficult. We were not able to disentangle measurement variability and normal tissue heterogeneity due to the fact that studying reproducibility of DCE-MRI is not feasible in a human population because of the burden of repeated contrast administration. However, Poot et al previously showed that with this DCE-MRI method, reproducibility is sufficient to allow identification of group differences in perfusion of 10% in k_{trans} or k_{ep} at a significance level of $P < 0.05$ with 75% power with our sample size.³¹ Given the new insight of high intersubject variability, however, and the fact that the minimal clinical relevant difference is unknown, a larger sample size could be needed to make sure small, yet significant differences are not missed.

In conclusion, higher values of patellar bone perfusion parameters, measured with quantitative DCE-MRI, were found in PFP patients compared to healthy control subjects, but these differences were not statistically significant. This result, and the observed significant difference in k_{trans} variance, warrant further research.

Acknowledgments

Contract grant sponsor: Dutch Arthritis Foundation; Contract grant sponsor: Erasmus University Rotterdam;

Contract grant sponsor: Hitachi Medical Systems/Radiological Society of North America Research Seed Grant.

The authors thank all participants and the caregivers for recruiting the participants. The funding sources had no role in the study design, collection, analysis or interpretation of data; in the writing of the article; or in the decision to submit the article for publication.

References

- DeHaven KE, Lintner DM. Athletic injuries: comparison by age, sport, and gender. *Am J Sports Med* 1986;14:218–224.
- Rathleff MS, Rathleff CR, Olesen JL, Rasmussen S, Roos EM. Is knee pain during adolescence a self-limiting condition?. Prognosis of patellofemoral pain and other types of knee pain. *Am J Sports Med* 2016; 44:1165–1171.
- Lankhorst NE, van Middelkoop M, Crossley KM, et al. Factors that predict a poor outcome 5-8 years after the diagnosis of patellofemoral pain: a multicentre observational analysis. *Br J Sports Med* 2016;50:881–886.
- van der Heijden RA, Lankhorst NE, van Linschoten R, Bierma-Zeinstra SM, van Middelkoop M. Exercise for treating patellofemoral pain syndrome. *Cochrane Database Syst Rev* 2015;1:CD010387.
- Callaghan MJ, Selfe J. Patellar taping for patellofemoral pain syndrome in adults. *Cochrane Database Syst Rev* 2012;4:CD006717.
- Barton CJ, Munteanu SE, Menz HB, Crossley KM. The efficacy of foot orthoses in the treatment of individuals with patellofemoral pain syndrome: a systematic review. *Sports Med* 2010;40:377–395.
- Swart NM, van Linschoten R, Bierma-Zeinstra SM, van Middelkoop M. The additional effect of orthotic devices on exercise therapy for patients with patellofemoral pain syndrome: a systematic review. *Br J Sports Med* 2012;46:570–577.
- Arnoldi CC, Lemperg K, Linderholm H. Intraosseous hypertension and pain in the knee. *J Bone Joint Surg Br* 1975;57:360–363.
- Hejgaard N, Diemer H. Bone scan in the patellofemoral pain syndrome. *Int Orthop* 1987;11:29–33.
- Naslund JE, Odenbring S, Naslund UB, Lundberg T. Diffusely increased bone scintigraphic uptake in patellofemoral pain syndrome. *Br J Sports Med* 2005;39:162–165.
- Naslund J, Walden M, Lindberg LG. Decreased pulsatile blood flow in the patella in patellofemoral pain syndrome. *Am J Sports Med* 2007;35:1668–1673.
- Ho KY, Hu HH, Colletti PM, Powers CM. Recreational runners with patellofemoral pain exhibit elevated patella water content. *Magn Reson Imaging* 2014;32:965–968.
- Lemperg RK, Arnoldi CC. The significance of intraosseous pressure in normal and diseased states with special reference to the intraosseous engorgement-pain syndrome. *Clin Orthop Relat Res* 1978:143–156.
- Selfe J, Harper L, Pedersen I, Breen-Turner J, Waring J, Stevens D. Cold legs: a potential indicator of negative outcome in the rehabilitation of patients with patellofemoral pain syndrome. *Knee* 2003;10:139–143.
- Li SP, Padhani AR. Tumor response assessments with diffusion and perfusion MRI. *J Magn Reson Imaging* 2012;35:745–763.
- Copen WA, Schaefer PW, Wu O. MR perfusion imaging in acute ischemic stroke. *Neuroimaging Clin N Am* 2011;21:259–283, x.
- Seah S, Wheaton D, Li L, et al. The relationship of tibial bone perfusion to pain in knee osteoarthritis. *Osteoarthritis Cartilage* 2012;20: 1527–1533.
- Lee JH, Dyke JP, Ballon D, Ciombor DM, Rosenwasser MP, Aaron RK. Subchondral fluid dynamics in a model of osteoarthritis: use of dynamic contrast-enhanced magnetic resonance imaging. *Osteoarthritis Cartilage* 2009;17:1350–1355.

19. Lee JH, Dyke JP, Ballon D, Ciombor DM, Tung G, Aaron RK. Assessment of bone perfusion with contrast-enhanced magnetic resonance imaging. *Orthop Clin N Am* 2009;40:249–257.
20. Breault SR, Heye T, Bashir MR, et al. Quantitative dynamic contrast-enhanced MRI of pelvic and lumbar bone marrow: effect of age and marrow fat content on pharmacokinetic parameter values. *AJR Am J Roentgenol* 2013;200:W297–303.
21. Budzik JF, Lefebvre G, Forzy G, El Rafei M, Chechin D, Cotten A. Study of proximal femoral bone perfusion with 3D T1 dynamic contrast-enhanced MRI: a feasibility study. *Eur Radiol* 2014;24:3217–3223.
22. Dyke JP, Aaron RK. Noninvasive methods of measuring bone blood perfusion. *Ann N Y Acad Sci* 2010;1192:95–102.
23. Brix G, Semmler W, Port R, Schad LR, Layer G, Lorenz WJ. Pharmacokinetic parameters in CNS Gd-DTPA enhanced MR imaging. *J Comput Assist Tomogr* 1991;15:621–628.
24. Tofts PS, Kermode AG. Measurement of the blood-brain barrier permeability and leakage space using dynamic MR imaging. 1. Fundamental concepts. *Magn Reson Med* 1991;17:357–367.
25. Poot DHJ, van der Heijden RA, van Middelkoop M, Oei EHG, Klein S. Dynamic contrast-enhanced MRI of the patellar bone: How to quantify perfusion. *J Magn Reson Imaging* 2018;47:848–858.
26. Witvrouw E, Crossley K, Davis I, McConnell J, Powers CM. The 3rd International Patellofemoral Research Retreat: an international expert consensus meeting to improve the scientific understanding and clinical management of patellofemoral pain. *Br J Sports Med* 2014;48:408.
27. Kujala UM, Jaakkola LH, Koskinen SK, Taimela S, Hurme M, Nelimarkka O. Scoring of patellofemoral disorders. *Arthroscopy* 1993;9:159–163.
28. Bron EE, van Tiel J, Smit H, et al. Image registration improves human knee cartilage T1 mapping with delayed gadolinium-enhanced MRI of cartilage (dGEMRIC). *Eur Radiol* 2013;23:246–252.
29. van Tiel J, Bron EE, Tiderius CJ, et al. Reproducibility of 3D delayed gadolinium enhanced MRI of cartilage (dGEMRIC) of the knee at 3.0 T in patients with early stage osteoarthritis. *Eur Radiol* 2013;23:496–504.
30. Klein S, Staring M, Murphy K, Viergever MA, Pluim JPW. elastix: A toolbox for intensity-based medical image registration. *IEEE Trans Med Imaging* 2010;29:196–205.
31. Poot DHJ, van der Heijden RA, van Middelkoop M, Oei EHG, Klein S. Dynamic contrast-enhanced MRI of the patellar bone: How to quantify perfusion. *J Magn Reson Imaging* 2018;47:848–858.
32. Sijbers J, den Dekker AJ. Maximum likelihood estimation of signal amplitude and noise variance from MR data. *Magn Reson Med* 2004;51:586–594.
33. Sanchis-Alfonso V, Rosello-Sastre E, Revert F, Garcia A. Histologic retinacular changes associated with ischemia in painful patellofemoral malalignment. *Orthopedics* 2005;28:593–599.