

Improved Simultaneous Multi-Slice Imaging for Perfusion Cardiac MRI Using Outer Volume Suppression and Regularized Reconstruction

Demirel, Omer Burak; Weingartner, Sebastian; Moeller, Steen; Akcakaya, Mehmet

DOI

[10.1109/ISBI45749.2020.9098326](https://doi.org/10.1109/ISBI45749.2020.9098326)

Publication date

2020

Document Version

Accepted author manuscript

Published in

ISBI 2020 - 2020 IEEE International Symposium on Biomedical Imaging

Citation (APA)

Demirel, O. B., Weingartner, S., Moeller, S., & Akcakaya, M. (2020). Improved Simultaneous Multi-Slice Imaging for Perfusion Cardiac MRI Using Outer Volume Suppression and Regularized Reconstruction. In *ISBI 2020 - 2020 IEEE International Symposium on Biomedical Imaging* (Vol. 2020-April, pp. 1954-1957). Article 9098326 (Proceedings - International Symposium on Biomedical Imaging; Vol. 2020-April). IEEE. <https://doi.org/10.1109/ISBI45749.2020.9098326>

Important note

To cite this publication, please use the final published version (if applicable).
Please check the document version above.

Copyright

Other than for strictly personal use, it is not permitted to download, forward or distribute the text or part of it, without the consent of the author(s) and/or copyright holder(s), unless the work is under an open content license such as Creative Commons.

Takedown policy

Please contact us and provide details if you believe this document breaches copyrights.
We will remove access to the work immediately and investigate your claim.

IMPROVED SIMULTANEOUS MULTI-SLICE IMAGING FOR PERFUSION CARDIAC MRI USING OUTER VOLUME SUPPRESSION AND REGULARIZED RECONSTRUCTION

Ömer Burak Demirel^{*†}, Sebastian Weingärtner^{*†‡}, Steen Moeller[†] and Mehmet Akçakaya^{*†}

^{*} Electrical and Computer Engineering, University of Minnesota, Minneapolis, MN, United States

[†] Center for Magnetic Resonance Research, University of Minnesota, Minneapolis, MN, United States

[‡] Department of Imaging Physics, Delft University of Technology, Delft, Netherlands

ABSTRACT

Perfusion cardiac MRI (CMR) is a radiation-free and non-invasive imaging tool which has gained increasing interest for the diagnosis of coronary artery disease. However, resolution and coverage are limited in perfusion CMR due to the necessity of single snap-shot imaging during the first-pass of a contrast agent. Simultaneous multi-slice (SMS) imaging has the potential for high acceleration rates with minimal signal-to-noise ratio (SNR) loss. However, its utility in CMR has been limited to moderate acceleration factors due to residual leakage artifacts from the extra-cardiac tissue such as the chest and the back. Outer volume suppression (OVS) with leakage-blocking reconstruction has been used to enable higher acceleration rates in perfusion CMR, but suffers from higher noise amplification. In this study, we sought to augment OVS-SMS/MB imaging with a regularized leakage-blocking reconstruction algorithm to improve image quality. Results from highly-accelerated perfusion CMR show that the method improves upon SMS-SPiRiT in terms of leakage reduction and split slice (ss)-GRAPPA in terms of noise mitigation.

Index Terms— Magnetic resonance imaging, parallel imaging, accelerated MRI, simultaneous multi-slice imaging, outer volume suppression, myocardial perfusion

1. INTRODUCTION

Coronary artery disease (CAD) is the leading cause of death in the US, accounting for one in six deaths [1]. CAD is clinically diagnosed based on invasive methods. Obtaining fractional flow reserve (FFR) measurements is currently considered the gold-standard [2]. However, invasive procedures have associated risks and costs. Myocardial perfusion cardiac MRI (CMR) has gained interest for functional assessment of stenosis [3]. A recent study has shown that CMR is associated with less revascularization and is noninferior to invasive FFR measurements [4]. However, long acquisition times remain a major hindrance for perfusion CMR, necessitating trade-offs between spatio-temporal resolution and coverage.

Perfusion CMR is acquired using single snap-shot imaging during the pass of a contrast agent to assess myocardial

blood flow and to detect ischemia [5]. Since all the k-space data needs to be acquired in a short temporal window, resolution and coverage are limited even though acceleration techniques are utilized clinically. Low resolution causes inaccurate assessment of perfusion abnormalities due to dark rim artifacts, while limited coverage may result in missed regions of relevance in microvascular disease [5]. Simultaneous multi-slice (SMS) imaging has gained interest in CMR as a means for improving coverage with minimal SNR loss [6]. Compared to other parallel imaging techniques, the only SNR loss in SMS imaging is due to coil geometry [7]. However, leakage artifacts from the back and chest wall limit the acceleration rates in CMR [6].

To enable higher SMS factors, OVS methods have been proposed in perfusion CMR [8, 9], where spatially selective pulses are used to suppress extra-cardiac tissue. The removal of such unwanted signal enables higher SMS factors, as well as additional in-plane acceleration [8]. However, perfusion CMR with these ultra-high acceleration factors (combining SMS with additional in-plane acceleration) suffers from noise amplification, especially when leakage-blocking reconstruction techniques are utilized [10].

In this work, we sought to improve the image quality of OVS-prepared SMS perfusion CMR using a regularized leakage-blocking SMS reconstruction algorithm, building on our earlier work [11, 12]. The proposed acquisition and reconstruction were evaluated on perfusion CMR, and compared to split slice (ss)-GRAPPA [10] and SMS-SPiRiT [13, 14].

2. METHODS

2.1. Imaging Experiments

Imaging was performed at 3T in a healthy subject. The study was approved by our institutional review board. Written informed consent was obtained. First-pass myocardial imaging was performed on the healthy subject with injection of 0.05 mmol/kg gadobutrol (Gadovist) at 4mL/s followed by a 10-mL saline flush.

Figure 1a depicts the sequence diagram of the OVS-SMS

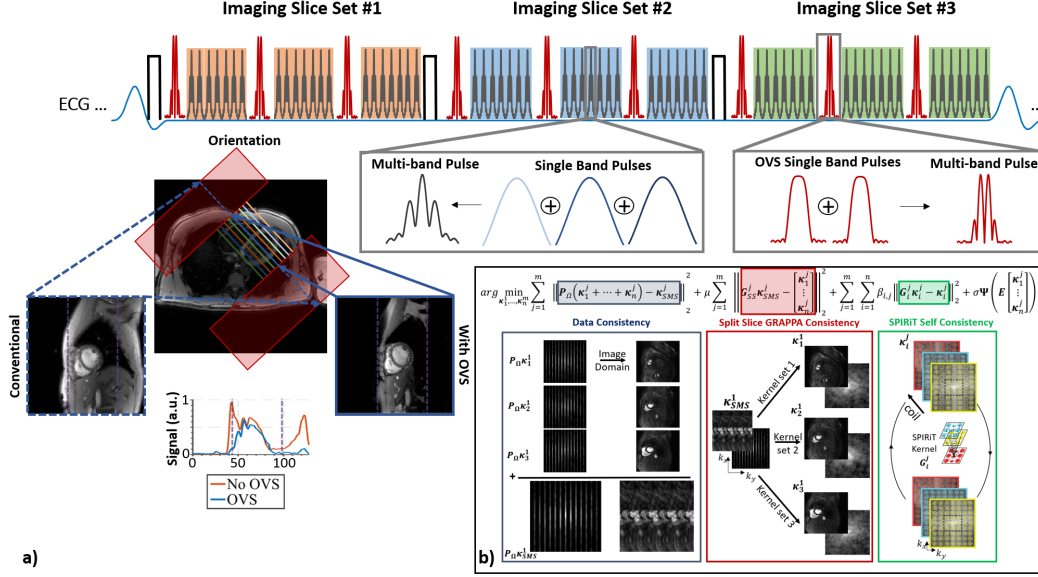


Fig. 1: a) Sequence diagram for the proposed OVS-SMS perfusion sequence. Sum of 3 sinc-pulses at different center frequencies are utilized for SMS GRE imaging. In each heart beat, 3 imaging slice sets (9 slices overall) are acquired with interleaved OVS pulses. To simultaneously saturate signals from the chest and back, two slab-selective OVS pulses are combined into a multiband OVS pulse. These rest slabs are shown with maroon rectangles for short-axis view. The resulting signal intensity after OVS is depicted underneath. **b)** A schematic of the proposed regularized reconstruction algorithm in Equation 1. Blue box represents the data consistency term with the acquired SMS k-space data. Red box represents the ss-GRAPPA consistency, providing noisy but reliable estimates of the individual k-spaces. Green box represents the SPIRiT self-consistency, which enforces coil self-consistency for each slice.

perfusion CMR. A saturation-prepared GRE sequence was used with SMS factor = 3. The three slices were simultaneously excited with controlled aliasing [7], where $2\pi/3$ phase shifts were utilized to reduce noise amplification. Three sets of SMS-accelerated slices were acquired for a total of 9 slices, covering the whole heart. OVS was performed with a multi-band combination of two slab-selective single band saturation pulses. These two parallel slabs were utilized in phase encode direction to suppress signal from chest wall and back simultaneously. Owing to the low specific absorption rate and duration of these OVS pulses, they were interleaved within the imaging window between every 9 imaging pulses [8].

Following imaging parameters were used: SMS factor = 3, in-plane acceleration = 4, partial Fourier 6/8, field-of-view (FOV) = $360 \times 360 \text{ mm}^2$, resolution = $1.7 \times 1.7 \text{ mm}^2$, slice-thickness = 8mm, TR/TE/FA = 2.9/1.7ms/12°, temporal resolution = 110ms, saturation time = 150ms, OVS module: saturation slab = 150mm (each side), 3.8ms asymmetric sinc, BWT = 8, RF peak shift = 15%. Calibration scan: Non-prepared GRE with FOV = $360 \times 360 \text{ mm}^2$, resolution = $1.7 \times 5.6 \text{ mm}^2$, slice-thickness = 8mm, 9 slices.

2.2. Reconstruction

The acquired raw data with 3-fold SMS and 4-fold in-plane acceleration with 6/8 partial Fourier, leading to overall 16-fold acceleration were exported from the scanner for offline processing. The proposed method builds on our earlier work

[11, 12]. For perfusion CMR, our method combines the advantages of ss-GRAPPA [10] in removing aliasing artifacts, and SPIRiT [15] in enforcing self-consistency while allowing further regularization. The proposed method enforces consistency with ss-GRAPPA, which provides reliable estimates with a cost of noise amplification, self-consistency among coils, and consistency with acquired data, as well as using a regularization term. A schematic description of the data consistency (first term), ss-GRAPPA consistency (second term) and SPIRiT coil self-consistency (third term) in Eq. 1 is depicted in Fig. 1b.

The following objective function is solved for each dynamic separately using ADMM:

$$\arg \min_{\kappa_1^j, \dots, \kappa_n^j} \sum_{j=1}^m \left\| \mathbf{P}_\Omega (\kappa_1^j + \dots + \kappa_n^j) - \kappa_{SMS}^j \right\|_2^2 + \mu \sum_{j=1}^m \left\| \mathbf{G}_{SS}^j \kappa_{SMS}^j - \begin{bmatrix} \kappa_1^j \\ \vdots \\ \kappa_n^j \end{bmatrix} \right\|_2^2 + \sum_{i=1}^n \sum_{j=1}^m \beta_{i,j} \left\| \mathbf{G}_i^j \kappa_i^j - \kappa_i^j \right\|_2^2 + \sigma \Psi \left(\mathbf{E} \begin{bmatrix} \kappa_1^j \\ \vdots \\ \kappa_n^j \end{bmatrix} \right) \quad (1)$$

where m is the number of imaging sets per heartbeat (three in our setting), n is the SMS factor (three in our setting), κ_i^j is the k-space data across all coils of the i^{th} slice of the j^{th}

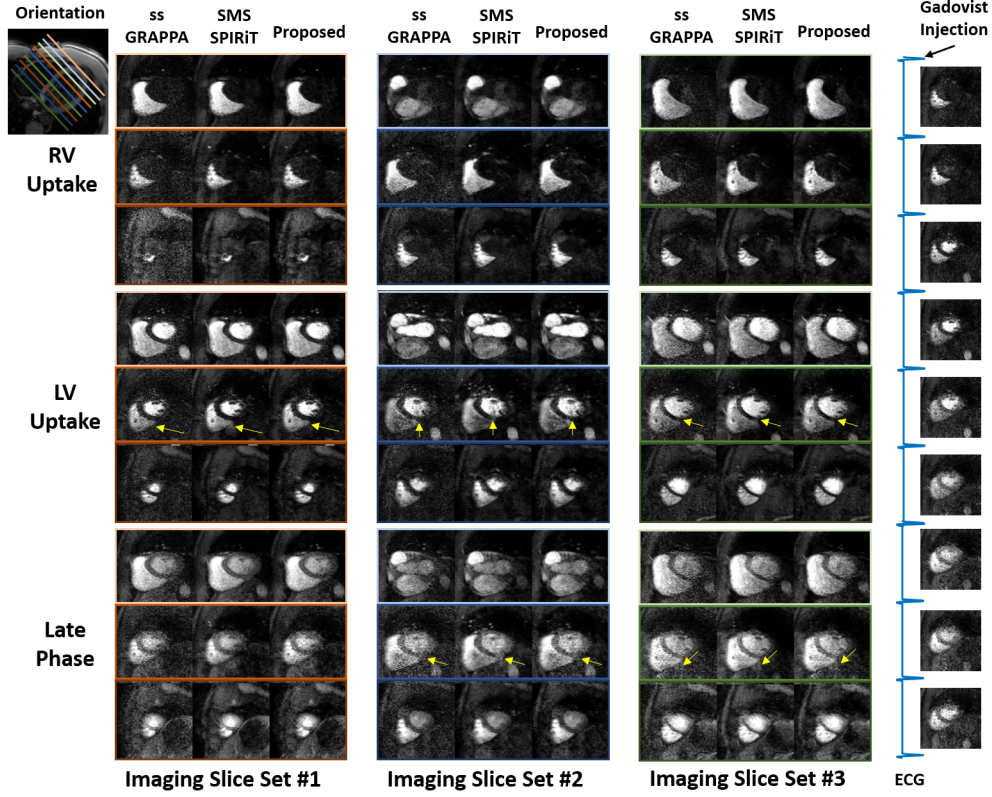


Fig. 2: The reconstructed perfusion images with 3-fold SMS/MB factor with 4-fold in-plane acceleration and 6/8 partial Fourier which is 16-fold overall acceleration is illustrated. ss-GRAPPA, SMS-SPIRiT and proposed method are utilized to reconstruct the images. Three imaging slice sets were reconstructed with all three techniques. ss-GRAPPA shows reliable but noisy images. SMS-SPIRiT shows leakage artifacts indicated with yellow arrows. The proposed method shows less noise without leakage artifacts.

set, \mathbf{P}_Ω is a sub-sampling operator that is a fixed uniform pattern for all imaging sets in a given dynamic, κ_{SMS}^j is the acquired SMS data across all coils in k-space for the j^{th} imaging set, \mathbf{G}_{SS}^j is the ss-GRAPPA operator for the j^{th} set, \mathbf{G}_i^j is the SPIRiT self-consistency operator for the i^{th} slice of the j^{th} set, \mathbf{E} is the concatenated SENSE-1 operator for all the nine slices in that acquired in that dynamic/heart-beat, Ψ is a regularizer, μ , $\beta_{i,j}$ and σ are weight terms. The regularizer was based on low-dimensional-structure self-learning and thresholding (LOST), which learns and uses anatomical structures in an image in a scan-specific manner using block matching [16]. For regularization all the 9 slices were processed together. No temporal information was shared unlike traditional perfusion regularization, thus avoiding any chance of temporal blurring. Furthermore, since block matching searches for similar blocks across different slices, no explicit slice tracking or registration is needed during regularization.

Images were reconstructed with ss-GRAPPA [10], SMS-SPIRiT [13, 14] and the proposed regularized reconstruction. 5×5 kernels were used for all ss-GRAPPA, \mathbf{G}_{SS}^j , and 7×7 kernels were used for all SPIRiT, \mathbf{G}_i^j , which were calibrated using the calibration scan. SMS-SPIRiT was implemented with the following parameters: $\mu = 0$, $\beta_{i,j} = 10^{-3}$ for all

i, j and $\sigma = 10^{-7}$ times ℓ_∞ norm of the SENSE-1 images of the slices. Proposed technique was implemented with parameters: $\mu = 10^{-4}$, $\beta_{i,j} = 10^{-3}$ for all i, j and $\sigma = 2.5 \cdot 10^{-6}$ times ℓ_∞ norm of the SENSE-1 images of the slices.

3. RESULTS

Figure 2 shows perfusion CMR results with SMS = 3 for 3 imaging sets, for a total of 9 slices for whole heart coverage, reconstructed with ss-GRAPPA, SMS-SPIRiT and proposed method. SMS-SPIRiT shows visible leakage artifacts (yellow arrows) compared to other methods. ss-GRAPPA eliminates leakage artifacts albeit at the cost of noise amplification. Proposed method shows improved image quality compared to SMS-SPIRiT and ss-GRAPPA with reduced noise.

4. DISCUSSION

In this study, we proposed a regularized leakage-blocking reconstruction for improving the quality of OVS-prepared perfusion CMR. In our previous works [11, 12], we used consistency with slice-GRAPPA [17] in the proposed method. Although slice-GRAPPA showed sufficient image quality at 8-

fold acceleration (SMS=3 × 2-fold in-plane × partial Fourier 6/8) [11, 12], it suffered from leakage artifacts in perfusion CMR due to the high 16-fold acceleration factor (SMS=3 × 4-fold in-plane × partial Fourier 6/8). Thus, in this work, we use consistency with ss-GRAPPA instead. ss-GRAPPA reduces leakage artifacts, albeit at the cost of higher noise amplification. Therefore the use of improved regularization strategies was also imperative. Regularization in perfusion CMR is traditionally utilized across the dynamics [18, 19]. However, in such cases the regularization trade-off needs to be carefully set in order to avoid issues related to temporal blurring. In this work, the regularizer was applied over the nine acquired slices at each dynamic without using temporal information. Thus, any potential temporal blurring due to shared temporal information was avoided.

5. CONCLUSION

The combination of OVS-SMS and regularized leakage-blocking algorithm shows promising results for highly-accelerated perfusion CMR with improved image quality.

6. ACKNOWLEDGMENT

This work was partially supported by NIH R00HL111410, NIH P41EB027061 and NSF CAREER CCF-1651825. Ö.B. Demirel was partially supported by an AHA Predoctoral Fellowship.

References

- [1] E. J. Benjamin, P. Muntner, et al., “Heart disease and stroke statistics-2019 update: a report from the American Heart Association,” *Circulation*, vol. 139, no. 10, pp. e56–e528, 2019.
- [2] P. A. L. Tonino, B. De Bruyne, et al., “Fractional flow reserve versus angiography for guiding percutaneous coronary intervention,” *NEJM*, vol. 360, pp. 213–224, 2009.
- [3] R. Watkins, S. and McGeoch, T. Lyne, J. and Steedman, et al., “Validation of MR myocardial perfusion imaging with fractional flow reserve for the detection of significant coronary heart disease,” *Circulation*, vol. 120, pp. 2207–2213, 2009.
- [4] E. Nagel, J. P. Greenwood, et al., “Magnetic resonance perfusion or fractional flow reserve in coronary disease,” *NEJM*, vol. 380, no. 25, pp. 2418–2428, 2019.
- [5] M. Jerosch-Herold, “Techniques for MR myocardial perfusion imaging,” in *J Cardiovasc Magn Reson*, pp. 99–112. Springer, 2019.
- [6] S. Weingärtner, S. Moeller, et al., “Simultaneous multislice imaging for native myocardial T1 mapping: Improved spatial coverage in a single breath-hold,” *Magn Reson Med*, vol. 78, no. 2, pp. 462–471, 2017.
- [7] F. A. Breuer, M. Blaimer, et al., “Controlled aliasing in parallel imaging results in higher acceleration (CAIPIR-INHA) for multi-slice imaging,” *Magn Reson Med*, vol. 53, no. 3, pp. 684–691, 2005.
- [8] S. Weingärtner, S. Moeller, and M. Akçakaya, “Feasibility of ultra-high simultaneous multi-slice and in-plane accelerations for cardiac MRI using outer volume suppression and leakage-blocking reconstruction,” in *Proc ISMRM*, 2018.
- [9] Y. Yang, L. Zhao, et al., “Reduced field of view single-shot spiral perfusion imaging,” *Magn Reson Med*, vol. 79, no. 1, pp. 208–216, 2018.
- [10] S. F. Cauley, J. R. Polimeni, H. Bhat, L. L. Wald, and K. Setsompop, “Interslice leakage artifact reduction technique for simultaneous multislice acquisitions,” *Magn Reson Med*, vol. 72, no. 1, pp. 93–102, 2014.
- [11] O. B. Demirel, S. Weingärtner, S. Moeller, and M. Akçakaya, “Multi-band SPIRiT strategies for improved simultaneous multi-slice myocardial T1 mapping,” in *Proc ISMRM*, 2019.
- [12] O. B. Demirel, S. Weingärtner, S. Moeller, and M. Akçakaya, “Improved regularized reconstruction for simultaneous multi-slice cardiac MRI T1 mapping,” in *EUSIPCO*, 2019.
- [13] Y. Yang, C. H. Meyer, F. H. Epstein, C. M. Kramer, and M. Salerno, “Whole-heart spiral simultaneous multi-slice first-pass myocardial perfusion imaging,” *Magn Reson Med*, vol. 81, no. 2, pp. 852–862, 2019.
- [14] C. Sun, Y. Yang, et al., “Non-Cartesian slice-GRAPPA and slice-SPIRiT reconstruction methods for multiband spiral cardiac MRI,” *Magn Reson Med*, 2019.
- [15] M. Lustig and J. M. Pauly, “SPIRiT: iterative self-consistent parallel imaging reconstruction for arbitrary k-space,” *Magn Reson Med*, vol. 64, pp. 457–471, 2010.
- [16] M. Akçakaya, T. A. Basha, et al., “Low-dimensional-structure self-learning and thresholding: regularization beyond compressed sensing for MRI reconstruction,” *Magn Reson Med*, vol. 66, no. 3, pp. 756–767, 2011.
- [17] K. Setsompop, B. A. Gagoski, et al., “Blipped-controlled aliasing in parallel imaging for simultaneous multislice echo planar imaging with reduced g-factor penalty,” *Magn Reson Med*, vol. 67, pp. 1210–1224, 2012.
- [18] S. G. Lingala, Y. Hu, E. DiBella, and M. Jacob, “Accelerated dynamic MRI exploiting sparsity and low-rank structure: k-t SLR,” *IEEE Trans Med Imaging*, vol. 30, no. 5, pp. 1042–1054, 2011.
- [19] Y. Q. Mohsin, S. G. Lingala, E. DiBella, and M. Jacob, “Accelerated dynamic MRI using patch regularization for implicit motion compensation,” *Magn Reson Med*, vol. 77, no. 3, pp. 1238–1248, 2017.